

Case Report:

CBCT-assisted Treatment of the Failing Long-Span Bridge with Staged and Immediate Load Implant Restoration

by Scott D. Ganz, DMD

Treating failed long-span bridges presents unique challenges for the clinician and the patient. When anchor abutment teeth fail, and it is recommended that the bridge be removed, often it can no longer be supported by natural teeth. The treatment option to replace the missing dentition would consist of a removable-type prosthesis, or an implant-retained restoration. Most patients do not want to be without teeth for an extended amount of time and desire the option which most closely replaces their missing teeth – a fixed prosthesis. In fact, many patients are now aware of treatment options which would allow for removal of the failing bridge and anchor teeth, followed by the immediate placement of dental implants to maintain an immediate transitional restoration. However, in order to present this treatment option to the patient, proper diagnosis and treatment planning is essential for a complete understanding of the available bone, soft tissue, opposing occlusion, vertical dimension and surrounding vital structures. Current two-dimensional panoramic and periapical radiographs can no longer be considered the most accurate diagnostic imaging modalities available.

To properly assess the patient's anatomy, I recommend a three-dimensional assessment utilizing Cone Beam CT scan (CBCT) technology, which empowers the clinician with new tools to make educated decisions regarding the plan of treatment.

Case Presentation

A 61-year-old male patient presented with pain and mobility in an existing posterior right mandibular long-span fixed bridge. A routine diagnostic work-up was completed, including periapical radiographs and study casts. The patient had a history of bruxism, which may have been contributory to the root fractures and mobility of the bridge. Radiographic loss of bone was evident around the mandibular second molar tooth, the termi-

nal abutment for the fixed bridge, which exhibiting a significant angular defect on the mesial (Fig. 1). The first bicuspid had previously been treated with root canal therapy, and appeared to be fractured from the stress of the restoration or recurrent decay along the margins. In order to determine the potential treatment alternatives, a CBCT scan was ordered to allow complete inspection of the three-dimensional bony topography, and the relationship of adjacent vital structures. Two-dimensional imaging modalities could not provide an adequate interpretation of the patient anatomy, raising the risk of treatment and potential injury to vital structures.

CBCT technology allows for an accumulation of data to accurately determine educated treatment decisions. There are four important three-dimensional views: (1) axial, (2) cross-sectional, (3) panoramic, and (4) 3D recon-

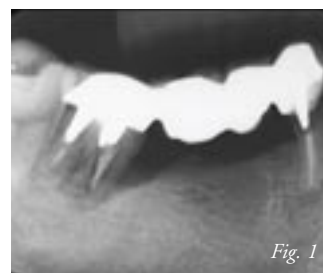

Fig. 1

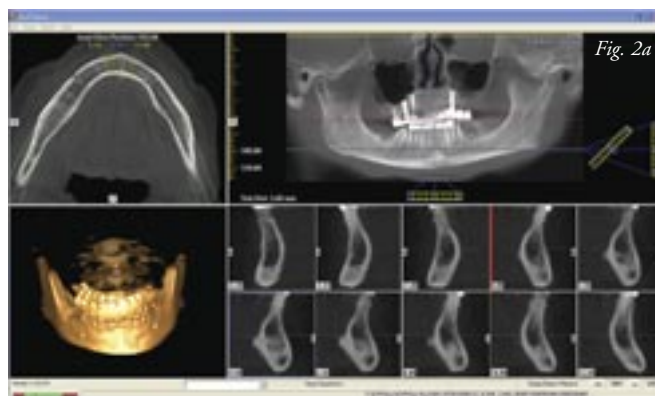

Fig. 2a

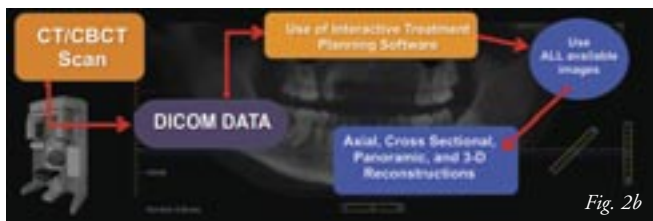

Fig. 2b

structions (Fig. 2a). Each of these views are individually important and when assimilated in total, due to the interactive nature of the CBCT viewing software, provides the ultimate overview of the patient's anatomic presentation. The data can be visualized utilizing interactive treatment planning software applications which have innovative tools to aid in the diagnosis and treatment planning. I have long advocated the concept "It's not the scan, it's the plan," meaning the clinician must evaluate the data provided by the CBCT machine. Once the scan is taken, it can be viewed on the computer workstation using the native software or the DICOM data can be exported into an interactive treatment planning software where all available images can be processed and manipulated interactively to create an excellent diagnostic environment (Fig. 2b).

Three-Dimensional Planning

The panoramic image reconstructed from the CBCT dataset differs substantially from a conventional panoramic radiograph. This non distorted image can be viewed interactively using the incorporated viewing software to assess the broader aspects of the arches (Fig. 3). The cross-sectional image is excellent for defin-

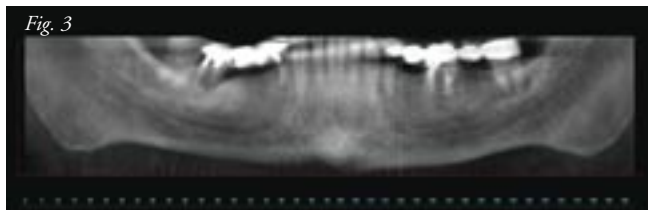


Fig. 3

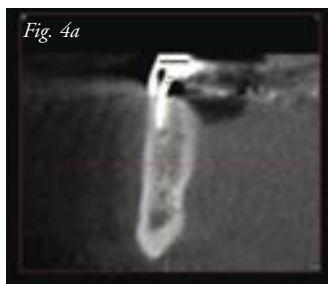
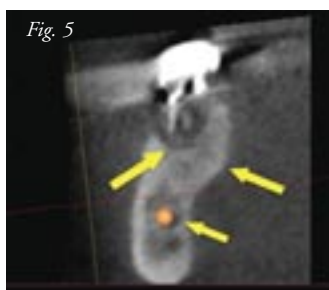
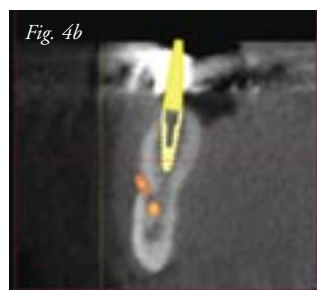


Fig. 4a

ing a slice of the mandible where the height and width of the bone can be accurately evaluated. Within an individual slice, the spatial location of the tooth and root can be appreciated (Fig. 4a). The facial, lingual cortical and intermedullary bone can

be visualized based upon their radiopacity or grayscale density values. Nuances within the anatomical presentation can be assessed with greater accuracy than with any other imaging modality. Simulated implants can be placed in a position to effectively support the desired restoration, even with close proximity to the mental foramen (Fig. 4b). The cross-sectional slice of the posterior molar reveals the significant bone defect sur-

continued on page 84



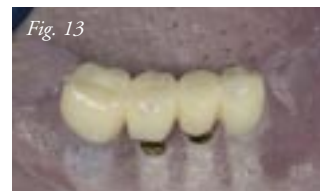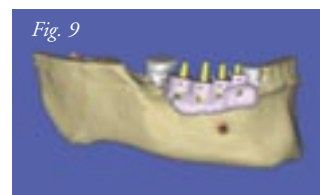
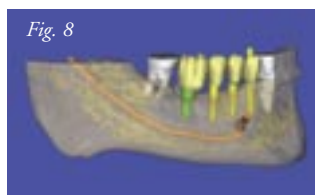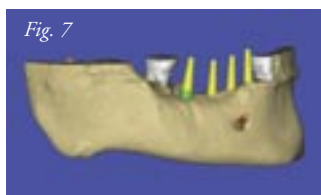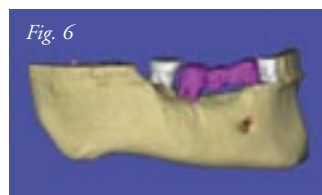rounding the apical roots (Fig. 5). There was cortical bone below the root apex and the significant lingual concavity was noted. The inferior alveolar nerve can be carefully traced through the mandible to determine proximity to the tooth roots and potential implant receptor sites (orange). Although there was good quality bone above the location of the nerve, there was insufficient bone to adequately fixate an implant. It was therefore elected to extract the molar tooth and fill the defect with grafting material in anticipation of placing an implant after the new bone had matured.

Creating a fully interactive three-dimensional reconstruction from the CBCT scan data allows the clinician further insight into the patient's existing anatomical presentation. Utilizing advanced software masking or segmentation enables the various anatomical entities to be separated for improved diagnostic capabilities. The pre-existing bridge has been colored (magenta) as have the adjacent molar and cuspid teeth (white) (Fig. 6). Simulated implants were positioned within the bone to support a new fixed restoration based upon the abutment projections which extended above the occlusal table (Fig. 7). Using advances in interactive software, "selective transparency" can be applied to change the opacity of various structures to aid in the diagnosis and planning phase. Accurate placement of realistic implants is enhanced by masking the adjacent tooth roots. The path of the inferior alveolar nerve can also be fully appreciated. Note the planned parallelism of the four simulated implants (Fig. 8). If the pre-existing restoration could not be physically removed in advance of

CT/CBCT imaging and the old occlusion was found to be unfavorable, through further masking or segmentation, it is now possible to build a virtual occlusion using interactive treatment planning software. "Virtual teeth" (seen in yellow) can correct discrepancies, and allow for an ideal simulated morphology fabrication. The large defect around the molar was significant, and it was determined that it could not be used as a receptor site initially. It was elected to graft this site, and return in five months to place a single implant in the molar site. Once the plan has been verified in all four available 3D views, a virtual template can be fabricated based upon the implant positions (Fig. 9). Therefore, the final surgical template is only as good as the virtual plan.

There are three basic CT-derived template types which can be fabricated for dental implant placement: (1) bone borne, (2) tooth-borne, and (3) soft tissue borne. Based upon the fact that there were adjacent teeth in the region, it was elected to utilize a tooth borne template stabilized by the existing occlusion. The CBCT scan data was sent via e-mail for fabrication of a stereolithographic model (Fig. 10).¹ This model is a replica of the patient's anatomy at the time that the images were acquired. The pre-existing bridge was removed via the software prior to fabrication of the surgical guide. The template adapts well to the surrounding dentition and does not require further fixation to prevent movement. The stainless steel tubes 0.2mm wider than the manufacturers' sequential osteotomy drills.

My novel modality utilizes a CT-derived stereolithographic model-based approach to link the implant placement and the eventual restoration. Implant replicas, or analogs were placed in pre-designated implant receptors on the stereolithographic partially edentate mandible (Fig. 11). In order to accommodate the immediate restoration, manufacturers' specific abutments were placed on the implant replicas. Note the interimplant distances for proper embrasure design. A diagnostic wax-up was accomplished and a clear matrix fabricated to facilitate the fabrication of a provisional prosthesis. Stock, 3inOne (BioHorizons) tita-



1. Materialise Dental, Lueven, Belgium

nium abutments were positioned on the implant replicas to support the temporary restoration (Fig. 12a). The processed four-unit transitional acrylic bridge was supported by the

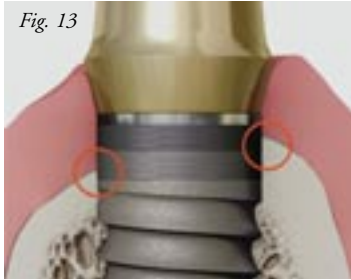


Fig. 13

implant abutments (Fig. 12b). As the molar site would not receive an implant immediately, a distal cantilever pontic was required. The actual implants, as simulated in the virtual plan, were chosen in advance, as well as how to best position the

implants to take advantage of the reverse buttress thread design, coronal microchannels and internal hexagonal connection design features. The tapered internal implants with the Laser-Lok microchannels allow for the implants to be placed in a “transitional” position where the lingual cortical plate is higher than the facial cortical plate of bone (Fig. 13).

Surgical Intervention

The occlusal view of the failing long-span bridge can be seen in Fig. 14a. Once the failed restoration was removed, the underlying fractured tooth roots were assessed. The volumetric change in the pontic areas was assessed by comparing the facial lingual dimensions of the molar and bicuspid with the pontic area with diminished keratinized tissue (Fig 14b). All of the planning decisions had been made prior to the surgical intervention except the design of the flap to expose the underlying alveolar ridge. To preserve the keratinized tissue, a full thickness muco-periosteal flap was required, followed by extraction of the two natural abutment teeth (Fig. 15). The tooth-borne template was then placed over the site and examined for fit (Fig. 16). As per the CBCT-derived plan and template, the first three implants were placed. The implants were well fixated allowing for immediate restoration by aligning the internal hexagonal connection to the facial with the attached

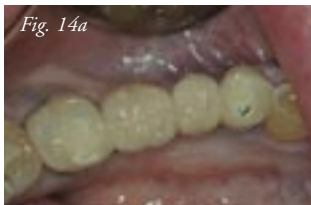

Fig. 14a

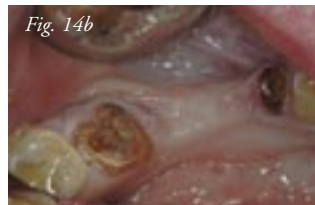


Fig. 14b

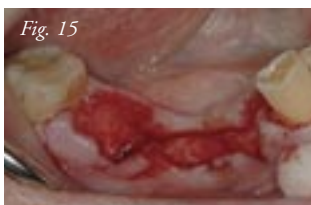
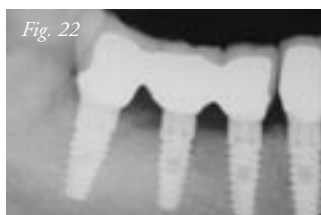
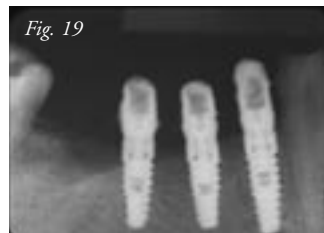


Fig. 15

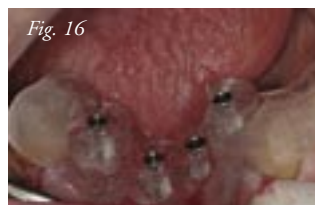

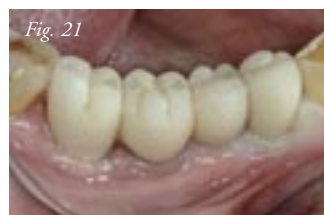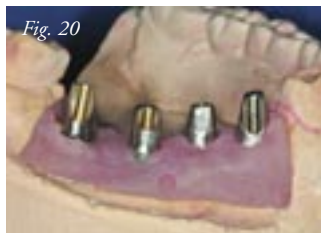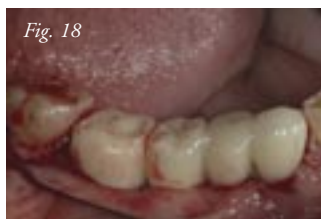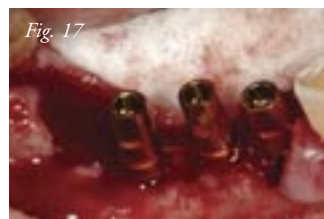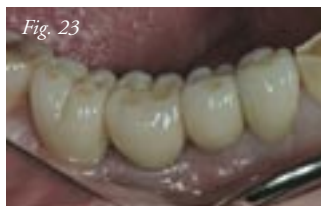Fig. 16

continued on page 86



3inOne abutments (Fig. 17). The posterior molar extraction socket was filled with a cortico-cancellous mineralized bone graft material (Miner-Oss, BioHorizons).



The pre fabricated four-unit provisional restoration was seated and relined to fit the three anterior implant fixtures. The distal-extension cantilever replaced the missing molar with care taken not to place pressure on the underlying graft. The soft tissue was sutured to allow for near primary closure as they were wrapped around the abutment projection while helping to establish embrasures (Fig. 18). The postoperative periapical radiograph confirms the placement of the anterior three implants and the bone graft in the molar defect (Fig. 19). The transitional restoration was cemented, retained and left in place for more than two months. Once the posterior molar bone graft had matured, the fourth implant was placed according to the original CBCT plan. When the fourth implant had integrated after eight weeks in function, an abutment was connected, and the existing transitional restoration was relined. Impressions were made and a soft tissue working cast fabricated for the laboratory process. The favorable parallelism afforded by the CBCT-derived planning required only minor preparation of the implant abutments to allow for adequate clearance for the metal alloy and porcelain veneer (Fig. 20).

Due to the patient's bruxism, it was elected to splint the posterior three units within the framework of the ceramo-metal restoration, while the anterior, longer implant was fabricated as

a single unit. The bisque-bake try-in revealed improved soft tissue contours and emergence profile (Fig. 21).

The completed ceramo-metal units seen in the periapical radiographs show nice parallelism and interimplant distances (Fig. 22). The emergence profile of each implant illustrates a smooth transition important to long-term maintenance. The final glaze and porcelain characteristics of the posterior four units blend in nicely with the surrounding dentition and soft tissue (Fig. 23). Note the excellent adaptation of the embrasures.

The purpose of this case presentation is to illustrate the enhanced diagnostic and treatment planning capabilities of CBCT data combined with interactive treatment planning software. The combination of careful diagnosis with proper planning aides the clinician in understanding existing bone topography, bone density, adjacent tooth roots, lingual concavities, occlusion, and the path of the inferior alveolar nerve. Once the information has been gathered, an accurate plan can be established. This plan will then be transferred to a surgical guide, allowing for precise implant placement. In a phased approach, three initially placed implants were immediately loaded with a transitional cantilever restoration, while avoiding the lingual concavity and within a zone of safety above the inferior alveolar nerve. The posterior molar tooth with resulting socket defect was found to be unfavorable for implant fixation, and therefore site development was accomplished with bone grafting. This was anticipated and documented preoperatively after interpretation of the CBCT data. Once matured, the molar area became an excellent implant receptor site. The patient was given a transitional restoration the day of surgery, although there was a staged approach and delayed implant placement in the molar area. This case represented one treatment alternative to replacing a failed long-span mandibular and bridge which was made possible through CBCT scan technology, interactive treatment planning software and CT-derived surgical templates to guide the placement of the implants based upon the restorative needs of the patient. ■

Author's Bio

Dr. Scott D. Ganz presents extensively on national and international podiums on the Prosthetic and Surgical phases of Implant Dentistry and is considered one of the world's leading experts in the field of Computer Utilization for Diagnostic, Graphical and Treatment Planning Applications in Dentistry. Dr. Ganz has published more than 60 articles, many textbook chapters, and currently serves as associate editor for the peer-reviewed journal, *Implant Dentistry*, and president of the Computer Aided Implantology (CAI) Academy. For more information, visit www.drganz.com.

