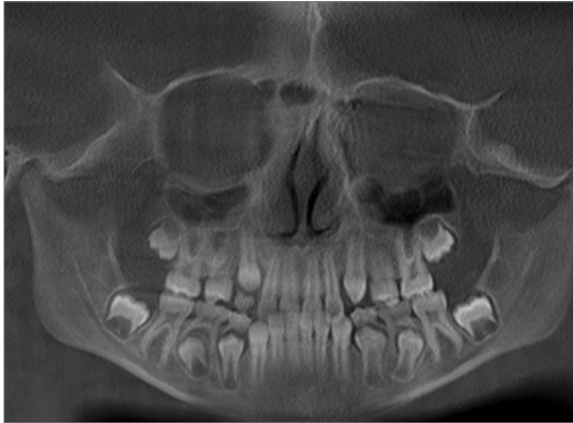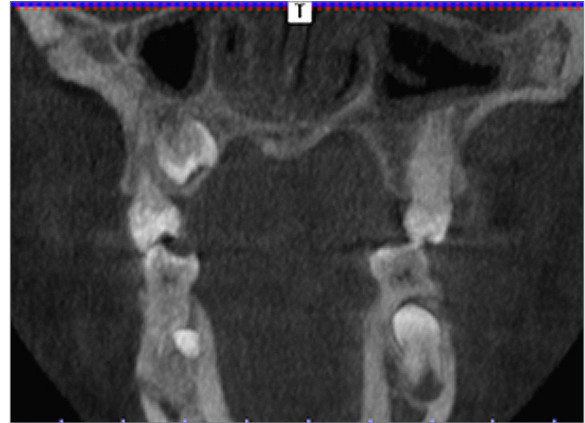


## Diagnosis of Dental Development Improved by i-CAT® 3D Imaging



*True anatomical picture is not revealed with "2D" view*



*"Hidden" tooth is visible with 3D coronal view*

Orthodontists are expected to transform complex malocclusions into perfect bites. i-CAT® technology shows us vital details that are often invisible on 2D images such as impactions, supernumeraries, root angulations and distance between roots and adjacent teeth. As we gather more information prior to starting treatment, we are likely to have more predictable and consistent results. We no longer have to guess about the presence or absence of possibly impacted teeth or their locations.

In this case, an 11-year-old female with mixed dentition was referred to my office because of overcrowding. On the panoramic X-ray, it appeared as though these teeth may have been missing, when, in fact, the 3D scan clearly showed that tooth #4 was present and was developing palatal to tooth #5, while tooth #13 was absent. The CBCT scan

*...Case continued on next page*



### **Allen Gandy, DDS, MS**

Dr. Gandy is a board-certified orthodontist. He is a graduate of the University of Texas at Arlington, and Baylor College of Dentistry. He completed his post-doctoral specialty training in Orthodontics and Dentofacial Orthopedics and his Masters of Science degree in Oral Biology at the University of Nebraska Medical Center. Dr. Gandy lectures on 3D imaging and its applications to orthodontics. Dr. Gandy has private practices in Frisco and Fairview, Texas. He is an active member of the American Association of Orthodontists, and a Diplomate of the American Board of Orthodontics.

also showed that tooth #4 had minimal root development at that time. Treatment choices involved the possibility of extraction(s) and/or replacement of tooth #13. Without knowledge of the palatal tooth that was gained by the i-CAT® scan, it was also likely that a “surprise” tooth could have erupted later on during treatment. The patient and her parents were happy that our 3D scan had clearly illustrated which teeth were present. This information also opened up more options for treatment.

We are now monitoring the child’s dental development and waiting to see if tooth #4 develops properly. The current plan entails treating the left side to the current class II occlusion, since tooth #13 was already missing. On the right side, space will be opened and tooth #4 will be brought into occlusion. Therefore, no teeth will have to be extracted. Because of the CBCT scan, we may have saved the patient from undergoing an extraction, and will not have to alter treatment due to unforeseen eruptions. CBCT i-CAT® technology allows us to eliminate guesswork in many orthodontic situations.

### Why 3D, Why i-CAT®

Because it’s three-dimensional, i-CAT imaging technology gives us more information than 2D radiographs to plan orthodontic treatment, while minimizing guesswork from our diagnoses. 3D technology is also a powerful tool in educating our patients. In this case, the patient and her parents had never seen a 3D scan before and were grateful for what the scan could detect. They were also impressed that my office had implemented this amazing technology to better serve their needs.